



**DATE** 12/13/2022  
**PRESENTING CLINICAL SIGNS** Patient presented for abdominal ultrasound due to abdominal ascites visualized on radiographs, weight loss, and jaundice. Abdominal ascites was sampled and a clear, yellow, watery fluid was obtained. Fluid was also sent out for cytospin/fluid analysis which is pending

**INTERPRETED BY** L.D. McGill, DVM, Ph.D, DACVP  
**CYTOLOGY SUBMISSION** Abdominal ascites.

**PATIENT** "Rosie" Oringer  
**OBSERVATIONS** Abdominal fluid: Submitted are a large number of images of cells collected from the abdominal fluid in Rosie. The cellularity is supporting large numbers of reactive mesothelial cells which are macrophages with foamy cytoplasm. Scattered neutrophils are identified. The neutrophils are not septic. I was unable to identify bacteria.

**SPECIES** Feline  
**INTERPRETATION OF THE FINDINGS & FURTHER RECOMMENDATIONS** Abdominal fluid - Markedly reactive mesothelial cells with scattered non-degenerate neutrophils.

**BREED** DSH  
**COMMENTS** The cellularity in this collection is not specific for any neoplastic process or septic process. It supports a marked fluid buildup with mild inflammation. This inflammation could be from feline infectious peritonitis but it could also be the result of inflammation occurring secondarily to other conditions in the abdominal cavity including the potential of pancreatitis or enteritis. A guarded to unfavorable prognosis is warranted since the underlying cause is not confirmed in this fluid.

**SEX** Female spayed  
**AGE** 6-year-old  
**WEIGHT** 5.8 lbs

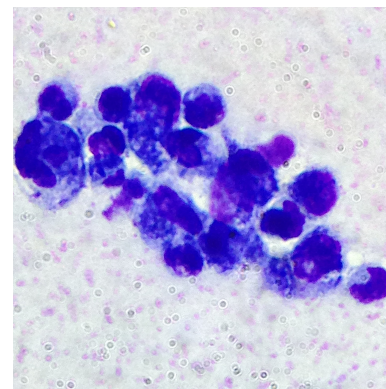
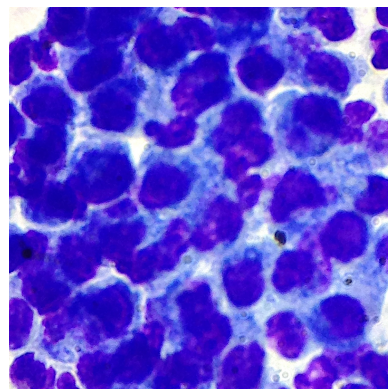


Image shows reactive mesothelial cells and neutrophils collected from the fluid from Rosie. The neutrophils are not degenerate.

**HOSPITAL NAME** New Bridge VH  
**The information and recommendations provided are based on the images presented by the referring veterinarian. No evaluation can be communicated regarding pathology that was not visible in the image/video clips provided.**

**REFERRING VET** Dr. Abina Glennon  
Thank you for this referral. If the clinical or image interpretation does not parallel your findings or if I can be of any further assistance please contact me.

**L.D. McGill, DVM, Ph.D., DACVP**  
8288 Top of the World Drive  
Cottonwood Heights, UT 84121 [ldmcgill.vetpath@gmail.com](mailto:ldmcgill.vetpath@gmail.com) cell: 801-865-1220



**DATE**

12/13/2022

**INTERPRETED BY**

L.D. McGill, DVM,  
Ph.D, DACVP

**PATIENT**

"Rosie" Oringer

**SPECIES**

Feline

**BREED**

DSH

**SEX**

Female spayed

**AGE**

6-year-old

**WEIGHT**

5.8 lbs

**HOSPITAL NAME**

New Bridge VH

**REFERRING VET**

Dr. Abina Glennon